

# Infrascanner – White Paper

## A Handheld Brain Hematoma Detector

### Executive Summary

---

In the United States alone, approximately 2.87 million people experience a traumatic brain injury (TBI), culminating in 2.53 million hospital visits, 288,000 hospitalizations and 56,800 deaths per year.<sup>1</sup> This is a 53% increase since 2006 and is likely due to the increased awareness of the dangers of delayed medical treatment for concussions and other head injuries. TBI is a major public health problem among males ages 15 to 24, who account for two-thirds of childhood and adolescent head trauma patients. In addition, TBI is a severe problem among elderly people (age 75 years and older) of both sexes. Globally, there are over 27 million new cases of TBI every year, with age-standardized incidence rates of 369 per 100,000 population<sup>2</sup>.

Rapid triage, diagnosis and treatment are critical in minimizing the adverse consequences of the more serious TBI cases. Since many TBI cases occur in clusters and are part of complex, extensive trauma to the individual victim (stemming from automobile accidents, war-zone explosions, etc.), the challenges presented to on-site medical personnel are significant. For patients with moderate-to-severe TBI in particular, diagnosis within the first hour (the “golden” hour) of the traumatic event is critical<sup>3</sup>.

InfraScan, Inc. has developed the Infrascanner to provide a rapid evaluation of head trauma patients with possible intracranial hemorrhage. The technology is portable and noninvasive, allowing for repeated monitoring without concern for radiation dose. The Office of Naval Research (ONR), the United States Marine Corps (USMC) and the U.S. Army Medical Materiel Development Activity (USAMMDA) sponsored the development of the different generations of the Infrascanner.

The Marine Corps has determined the need to procure a hand-held, non-invasive, near infrared based diagnostic device to detect brain hematoma at the site of injury. The Infrascanner shall be a modernization to the Authorized Medical Allowance List (AMAL) 635, Battalion Aid Station (BAS) and used by medical elements of the USMC field forces as a practical solution to the early detection of intracranial hematomas. Each BAS will be supplied with two Infrascanner devices, and a supply of disposable fiber optic shields. Initial fielding quantities are approximately 200 Infrascanner devices with 20,000 disposable fiber optic shields at 100 shields per device.

### Brain Injury Overview

---

A TBI, one of two subsets of acquired brain injury, can result from a closed head injury (whereby the head suddenly and violently hits an object but the skull remains intact) or a penetrating head injury; the other subset of acquired brain injury is non-traumatic brain injury (e.g., stroke, meningitis). A highly individualized injury, TBI severity depends on the nature of the injury, strength of the force, area of the brain affected as well as physical and genetic variations among patients. The damage from TBI can be localized (focal), confined to one area of the brain, or diffuse (typically a concussion), involving more than one area of the brain.

Types of focal brain injury include bruising of brain tissue (contusion) and rupture of blood vessels inside the skull, thereby resulting in heavy bleeding (intracranial hemorrhage or hematoma). Hemorrhaging can occur inside of the skull but outside of the brain (extra-axial) or within the brain itself (intra-axial). Extra-axial hemorrhages can be further divided into epidural hematoma, subdural hematoma and subarachnoid hemorrhage. Intra-axial bleeding within the brain itself is called an intracerebral hematoma.

Diagnostic and treatment protocols mandate that a patient suffering from head trauma receive immediate medical assessment, including a complete neurological examination. The severity of the head trauma and the responsiveness of the patient in a Glasgow Coma Scale (GCS) evaluation will determine which diagnostic methods will be used for further evaluation. In a GCS evaluation, the patient is scored on his/her ability to open eyes, communicate verbally and demonstrate motor skills. However, the GCS evaluation can be very subjective based upon the individual administering the test and can also be hampered if the patient is under sedation or has restrictions on his/her ability to verbally communicate (i.e., the patient has been intubated).

For patients with mild-to-moderate injuries, further diagnostic tests may be limited to skull and neck X-rays to check for bone fractures. For patients that have demonstrated moderate-to-severe TBIs after undergoing a neurological examination, the gold standard imaging test is a computed tomography (CT) scan, which creates a series of cross-sectional X-ray images of the head and brain and can show bone fractures as well as the presence of hemorrhage, hematomas, contusions, brain tissue swelling, and tumors. Magnetic resonance imaging (MRI), which uses magnetic fields to detect subtle changes in brain tissue content and can show more detail than X-rays or CT, may be used after the initial assessment and treatment of the TBI patient.

TBIs can cause a host of physical, cognitive, emotional, and social effects. And the outcomes for TBIs can be anything from complete recovery to permanent disability or death. An estimated 5.3 million individuals in the United States are living with long-term or life-long disability associated with a TBI that resulted in hospitalization. Unlike most causes of traumatic death, a large percentage of the people killed by brain trauma do not die right away but rather days to weeks after the traumatic event. In addition, rather than improving after being hospitalized, some 40% of TBI patients deteriorate.<sup>4</sup> Primary injury (the damage that occurs at the moment of trauma when tissues and blood vessels are stretched, compressed, and torn) is not adequate to explain this degeneration. Rather, the deterioration is caused by secondary injury resulting from a complex set of biochemical cascades that occur in the minutes to days following the trauma.<sup>5</sup> These biochemical cascades are instigated by brain swelling and inadequate flow of oxygen and blood to the brain resulting from brain compression by the expanding brain hematomas. The aim of the Infrascanner is to catch those hematomas before they are able to do any brain damage and lead to a much earlier intervention to evacuate the expanding brain hemorrhages.

In addition to disability, TBI can lead to increased risks for other debilitating health conditions. Recent studies indicated that in the 1-3-year post-injury period, individuals with TBI are 1.8 times more likely to report binge drinking, 11 times more likely to develop epilepsy and 7.5 times more likely to die. Additionally, the problems in the post-injury period include a 1.5 times higher risk for depression, and 2.3 times and 4.5 times higher risks for Alzheimer's disease associated with moderate and severe head injuries, respectively.<sup>6</sup>

## Types of Intracranial Hematomas after Traumatic Brain Injury

Injury to the brain after trauma can be classified as focal or diffuse. Focal mass lesions are less common, but the importance of appropriate and timely surgical treatment is emphasized by the significantly poorer

outcome associated with mass lesions. In the Traumatic Coma Data Bank (TCDB) series<sup>7</sup>, the mortality rate after severe closed head injury was 39% with a focal lesion, compared to 24% with a diffuse injury. There are 3 major types of traumatic intracranial hematomas: (1) subdural, (2) epidural, and (3) intracerebral hematomas. Each of these lesions has characteristic clinical and CT scan findings, and can be present on admission to the hospital or can occur in a delayed fashion.

### Subdural Hematomas

The subdural hematoma is the most common focal intracranial lesion, occurring as the primary initial lesion in 24% of patients with severe closed head injuries in the TCDB<sup>7</sup>, and occasionally as a delayed lesion. The hematoma is between the dura and the brain, usually resulting from a torn bridging vein between the cortex and the draining sinuses. An acute subdural hematoma typically appears on a CT scan as a high-density, homogenous crescent-shaped mass paralleling the inner surface of the skull.

Most acute subdural hematomas require surgery. Despite surgical evacuation, the mortality rate in patients with subdural hematomas was 50% in the TCDB series. The rapidity of surgical evacuation and the degree of associated brain damage are major determinants of outcome. Several studies report a decrease in the early mortality or morbidity in patients who underwent an early evacuation of subdural hematoma.

### Epidural Hematomas

Epidural hematomas, or collections of blood between the skull and dura, are less common, occurring as the primary initial lesion in 6% of patients with severe closed head injuries in the TCDB series<sup>7</sup>. Epidural hematomas can be present on the admission CT scan or less commonly may develop at some later time. In a consecutive series of 161 patients with epidural hematoma, 8% had delayed formation of the hematoma<sup>8</sup>. The delayed epidural hematoma can develop after evacuation of a hematoma on the opposite side or after a hypotensive patient has been resuscitated. In addition, epidural hematomas can recur after surgical evacuation. In a study of 88 patients with post-operative hematomas, 47 patients with an epidural hematoma developed a post-craniotomy hematoma requiring a second surgical procedure<sup>9</sup>.

Although patients with subdural hematomas are usually immediately comatose, only a third of patients with an epidural hematoma are unconscious from the time of the injury, one third have a lucid interval, and one third are never unconscious. An epidural hematoma is almost always associated with a skull fracture (91% in adults, and 75% in children)<sup>10</sup>. The blood comes from torn dural vessels, usually arterial, from the fractured skull bone, or occasionally from torn venous sinuses. On CT scan, an epidural hematoma is characterized by a biconvex, uniformly hyperdense lesion. Associated brain lesions are less common than with subdural hematomas.

Most epidural hematomas require surgery, and mortality and morbidity of surgical evacuation is low if the patient is operated upon early. The outcome of the patient with an epidural hematoma depends on the neurological status at the time of surgery. The mortality rate varies from 0% for patients who are not in coma, to 9% of obtunded patients, to 20% for patient in deep coma.

### Intracerebral Hematomas

Intracerebral blood can take the form of a hematoma or a contusion. Intracerebral hematomas are more common, occurring as the primary lesion in 10% of the severe closed head injuries in the TCDB series<sup>7</sup>. Most intracerebral hematomas are visualized on CT scan as hyperdense mass lesions. They are typically located in the frontal and temporal lobes and can be detected on a CT scan immediately after the trauma. However, delayed intracerebral hematomas may also be manifest during the hospital course. A delayed

hematoma is one that is seen on a repeat CT scan within 24 to 48 hours of the injury or operation but is not present on the initial CT scan. Commonly, a delayed hematoma is associated with clinical deterioration.

Hemorrhagic contusions were present as the primary lesion in 3% of severe closed head injuries in the TCDB series<sup>7</sup>. Single contusions are located either below the region of the impact or opposite the region of impact. Contusions appear as heterogeneous areas of brain necrosis, hemorrhage, and infarct representing mixed-density lesions on CT scan. Multiple focal contusions have a “salt and pepper” appearance on CT scan.

The decision to operate on an intracerebral hematoma is based on the patient's general condition, associated brain injuries, site and size of the hematoma, the ICP, and the magnitude of the mass effect. Generally accepted indications for surgery include (1) a hematoma associated with mass effect or in the anterior temporal lobe or in the cerebellum, (2) progressive neurological deterioration, or (3) refractory intracranial hypertension.

### Delayed Intracranial Hematomas

Delayed intracranial hematomas are a treatable cause of secondary injury if identified early, but can cause significant disability or death if not promptly recognized and treated. CT scanning has revealed that delayed hematomas after head trauma are more common than had been previously suspected. Recurrent hematomas, postoperative epidural hematomas, and delayed traumatic intracerebral hematomas occur in up to 23% of patients with severe head injury. Mortality rates and the incidence of a poor neurological recovery are significantly increased in patients who develop delayed traumatic intracranial hematomas. Early identification, prior to neurological deterioration, is the key to successful surgical treatment.

Serial CT scans are the most reliable method for detecting a delayed hematoma. However, CT scans require that patients, many of whom are critically ill, be taken out of the intensive care unit, and the yield is relatively low if serial scans are obtained in all patients. Some clinical monitoring technique for accurate selection of patients requiring follow-up CT scanning would improve the yield. Nevertheless, current clinical monitoring techniques are not ideal for detecting delayed hematomas. Patients with delayed hematomas may appear to be relatively normal only to undergo sudden neurological deterioration, or may not exhibit a change in their neurological examination. Intracranial pressure (ICP) may be normal in up to 20% of patients harboring delayed hematomas that require surgery.

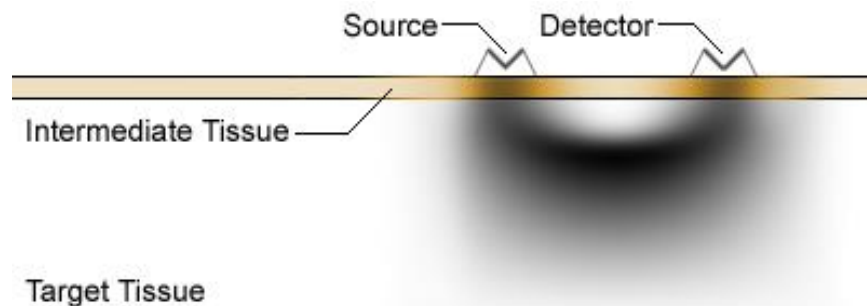
The ideal clinical monitor would be capable of making on-line continuous measurements in the intensive care unit, and would identify the development of a hematoma prior to the onset of clinical neurological deterioration. The technique of near-infrared spectroscopy (NIRS) may have these characteristics.

## Science and Technology

---

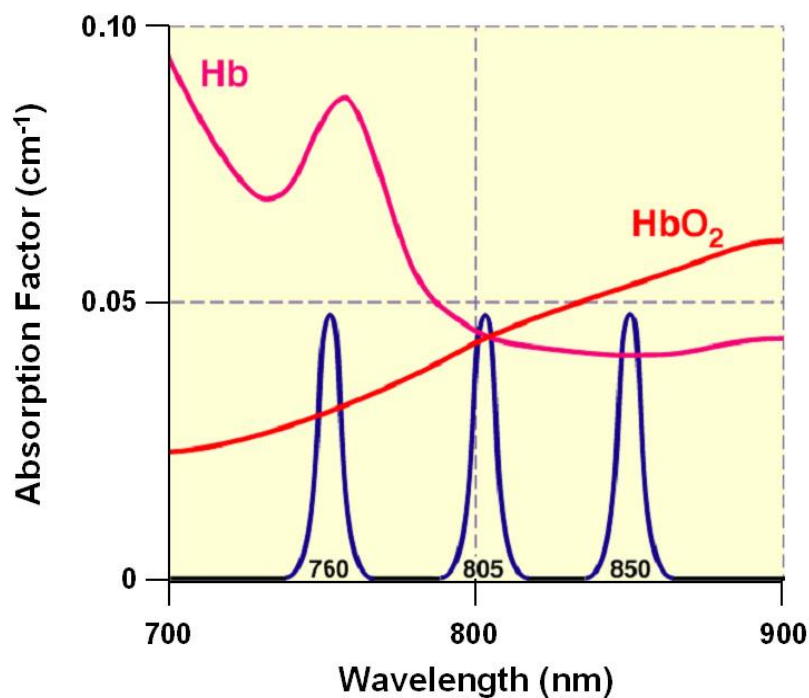
All biological tissue is, to differing extent, permeable to electromagnetic radiation of different frequencies and intensities. This can also be considered permeability to photons of different energy levels. This permeability to electromagnetic energy is the basis of all imaging based on transmission/scattering characteristics such as x-ray, Computed Tomography, and near-infrared, NIR, imaging. From the principles of spectroscopy, it is also known that different molecules absorb different wavelengths of electromagnetic radiation (which is synonymously referred to as light at shorter wavelengths). Similarly, tissue scatters radiation to different degrees. The Infrascanner is concerned with NIR imaging of the hemoglobin molecules. From any light source, photons follow a characteristic path through the target tissue back to a detector on the same approximate plane as the source. While the light is severely attenuated due to the

scattering and absorption process, it is nonetheless encoded with the spectroscopic signatures of the molecules encountered en route to the detector.



**Simulated photon diffusion path through target tissue from source to detector**

The principle used in identifying intracranial hematomas with the Infrascanner is that extravascular blood absorbs NIR light more than intravascular blood. This is because there is a greater (usually 10-fold) concentration of hemoglobin in an acute hematoma than in normal brain tissue where blood is contained within vessels. The Infrascanner compares left and right side of the brain in four different areas. The absorbance of NIR light is greater (and therefore the reflected light less) on the side of the brain containing a hematoma, than on the uninjured side. With specified wavelength ranges, optical light source(s) or emitter(s) and a photodetector are placed at a distance, which allows proper NIRS absorption measurements in a desired volume of tissue. The wavelength of 805nm is sensitive only to blood volume, not to oxygen saturation in the blood, as shown in the figure below.

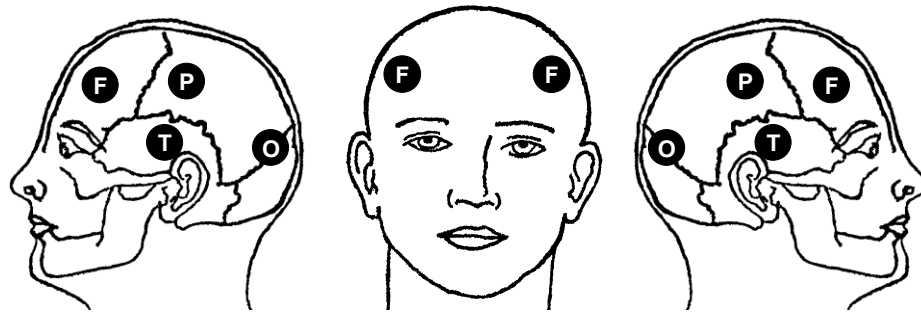


**Absorption of light by oxygenated and deoxygenated hemoglobin**

The Infrascanner is placed successively in the left and right frontal (F), temporal (T), parietal (P), and occipital (O) areas of the head and the absorbance of light is recorded. The difference in optical density ( $\Delta OD$ ) in each of the four symmetrical areas is calculated on a pair-wise basis from the following formula:

$$\Delta OD = \log_{10} \left( \frac{I_N}{I_H} \right) = \log_{10} (I_N) - \log_{10} (I_H)$$

where  $I_N$  = the intensity of reflected light on the normal side,  $I_H$  = the intensity of reflected light on the hematoma side.



**Head location of Infrascanner measurements**

<b>Frontal</b>	Left/Right forehead, above the frontal sinus with light guides above eye pupil
<b>Temporal</b>	In the Left/Right temporal fossa above the top of the ear
<b>Parietal</b>	Above the Left/Right ear, midway between the ear and the midline of the skull
<b>Occipital</b>	Behind the Left/Right ear, midway between the ear and the occipital protuberance

## The Devices



**Infrascanner Model 2000**



**Infrascanner Model 2500**

The Infrascanner includes two components: (1) the Scanner and (2) the Disposable Shield. Infrascanner Model 2000 includes a third component: A Cradle. Infrascanner Model 2500 is a miniaturized version of Infrascanner Model 2000. The Scanner includes a safe NIR diode laser and a silicon detector. The light to and from the laser and detector is optically coupled to the patient's head through the disposable shield optical fibers. The optical fibers are long enough to reach through hair and contact the scalp. The optical fibers are placed 4 cm apart allowing optimal detection of hematomas. The extended fiber optics eliminates the need to shave off any hair. And because the fiber optic piece is disposable it prevents cross contamination. The detected light passes through an optical NIR bandpass filter in order to minimize background light interference. Electronic circuitry is included to control laser power and the detector signal amplifier gain. The detector signal is digitized and analyzed by a single board computer, SBC, in the Scanner. The SBC receives the data from the detector and automatically adjusts the settings of the Scanner to ensure good data quality. The data is further processed by the SBC and the results are displayed on the screen. Readout of the scan provides information on the severity of a hematoma and identifies the region of the brain bleeding. A higher optical density in the scanned region indicates a larger hematoma.

## Military Application

---

### Operational Need

Traumatic brain injury (TBI) has become the defining injury in OIF and OEF<sup>1</sup>. Sixty percent of military service members wounded have sustained blast injuries, and two-thirds of them have TBI; of them 40% have brain hematomas. Rapid triage, diagnosis and treatment are critical in minimizing the adverse consequences of the more serious TBI cases. Since many TBI cases occur in clusters and are part of complex, extensive trauma to the individual victim, the challenges presented to on-site medical personnel are significant. For patients with moderate-to-severe TBI in particular, diagnosis within the first hour (the “golden” hour) of the traumatic event is critical as intracranial hematomas can result in death or significant

---

<sup>1</sup> OIF or OPIF – Operation Iraqi Freedom, OEF – Operation Enduring Freedom (the war in Afghanistan)

neurological impairment. Current SOP<sup>2</sup> involves an immediate clinical evaluation and neurological examination. Delayed hematomas also occur in significant numbers and may not be diagnosed until significant neurological impairment occurs. A CT scan is the definitive diagnostic modality. A rapid diagnosis, followed by immediate evacuation to a location, which has CT and neurosurgical intervention capability, is paramount to maximizing survivability and minimizing irreversible neurological impairment. The urgent need was identified by UUNS ISO<sup>3</sup> OPIF 08.01, dated 24 June 2008.

### Project History

Office of Naval Research funded the development of the technology in 2004 via SBIR Phase 1 and later via Phase 2 in 2007. Subsequently Infrascanner Model 1000 was developed, after attracting also \$1.5M in funding from Philadelphia based economic development agencies. A multicenter clinical study to support an FDA submission started in 2006, and in 2008 an application was submitted to the FDA. In 2010 the US Marines signed a SBIR CPP contract with InfraScan for development and field evaluation of a ruggedized version of the Infrascanner, named Infrascanner Model 2000. After 4 years of review, the FDA cleared Infrascanner Model 1000 as a DeNovo medical technology, and a year later, in 2013, the FDA cleared also the Infrascanner Model 2000. In 2014 US Marines signed SBIR Phase 3 contract to buy 200 Infrascanners, disposable shields and spare parts. In 2017 USAMMDA funded the development of the miniaturized Infrascanner Model 2500 and the FDA cleared the system in 2020.

### Field evaluations

Infrascanner was field tested by the Level III Fallujah Surgical initially and the Level II Shock Trauma Platoon (STP) of Combat Logistics Battalion 1 commencing February 2008 by CDR Dr. Luis Becerra of the Marines under special permit from Lt. General John Kelly. There were two sites with CT scanners in Iraq, Balad and Baghdad and the use of either required evacuation from Fallujah. Usually air evacuation is accompanied by significant risk and expense. Over 100 Marines and Sailors with closed head injury and concussion have been acutely evaluated with the device:

- About 90 subjects had a mild TBI and were not evacuated (Negative Infrascanners).
- Over one dozen with exposure to IED blasts were referred for CT to Balad and/or Baghdad in spite of negative Infrascanner findings. All CTs confirmed that there were no hematomas.
- Three positive Infrascanner cases were referred to immediate neurosurgical evaluation and treatment, including surgery (All confirmed by a later CT). The positive Infrascanner findings in those patients prompted expedited air evacuations.

Dr. Luis Becerra (US Marines):

“The Infrascanner located in Fallujah provided immediate information that was not available by any other means, and offered life-saving prioritization of patients who required immediate surgical intervention.”

In 2010 Infrascanner Model 1000 participated in JFCOM-TATRC Joint Capabilities Technology Demonstration at Ft. Detrick, MD. PJ Medics and corpsmen, who served either in Iraq or in Afghanistan, did the evaluation. The evaluation included a simulation of various casualty scenarios. The medics loved the system and in several of the scenarios it helped them to prioritize evacuation of casualties when they had restrictions on evacuation routes. Their feedback contributed several details to the design of the ruggedized Infrascanner model 2000.

In 2011 a study by the German Army doctors in Kunduz, Afghanistan<sup>11</sup>, evaluated a total of 11 TBI patients (military personnel and local civilians). Kunduz, in the north of Afghanistan, had a level 2 facility, where they used the Infrascanner Model 1000 for triage decisions to Mazar-e-Sharif, 100 miles away, where CT and Neurosurgical team are available. There were no intracranial hematomas in this group, as was

---

<sup>2</sup> SOP – Standard Operating Procedure

<sup>3</sup> UUNS – Urgent Universal Need Statement, ISO – In Support Of



confirmed by a later CT scan in Mazar-e-Sharif. The Specificity in this test was 100%. The user evaluation showed that the Infrascanner allows a preliminary estimate of an intracranial hematoma and that Infrascanner is easy to learn and can be repeatedly used even under emergency room conditions.

In 2011 MCSC conducted initial user evaluation of Infrascanner Model 2000 prototypes in Camp Pendleton with 1<sup>st</sup> medical battalion, led by AMEDD (Army Medical Department Board). The user evaluation was done by 12 users (6 corpsmen, 4 PAs and 2 MDs) and served as an input to the final design of the system.

In 2012 2<sup>nd</sup> battalion, 4<sup>th</sup> Marines performed a field evaluation in Helmand Province in Afghanistan of 4 prototypes of Infrascanner Model 2000. The 6-month evaluation ended with 15 helicopter evacuation flights saved (the evacuations were done by vehicles, due to negative Infrascanner reading).

Dr. Victor Jourdain (US Marines):

“The Infrascanner has proven to be an exceedingly valuable asset this deployment, both in finding problems and a lack of problems (therefore preventing a medical evacuation, saving tens of thousands of dollars, preserving limited assets and reducing lost man power).”

USAARL, the U.S. Army Aeromedical Research Laboratory, at Fort Rucker, AL tested successfully the Infrascanner Model 2000 and gave it AWR (Air Worthiness Rating) for Black Hawk, UH-60.

In 2018-2019 MRDC conducted a large field evaluation of several TBI detection technologies, including Infrascanner Model 2000<sup>12</sup>. The user feedback from this test was used to improve greatly the design of Infrascanner Model 2500 (system volume is a third of model 2000, weight of less than half a pound and able to scan 7 times more patients on one set of batteries, plus many other small changes, based on user feedback).

## Clinical Data

---

In a pilot study<sup>13</sup>, a NIRS examination was obtained in the ER at the time of the admission CT scan. Using an early prototype of the Infrascanner, called the “Runman”, serial measurements of  $\Delta OD$  were obtained in 305 head-injured patients. The maximal  $\Delta OD$  among the various regions examined was recorded for each patient and was correlated with the admission CT scan.  $\Delta OD$  on admission to the hospital was significantly elevated ( $>0.05$ ) in all but 4 (2%) patients with intracranial hematomas.  $\Delta OD$  was normal (0.00-0.05) in patients with diffuse brain injury (DBI). A single NIRS examination therefore reliably identified patients with an intracranial hematoma (98% had a  $\Delta OD > 0.05$ ), and gave a suggestion of whether the hematoma was intracerebral (most had a  $\Delta OD < 0.6$ ) or extracerebral (most had a  $\Delta OD > 0.6$ ).

The pivotal double blinded clinical study for FDA clearance<sup>14</sup> was carried out in five different clinical sites four of which are in the U.S: (1) Baylor College of Medicine, (2) Hahnemann Hospital, (3) The Hospital of the University of Pennsylvania and (4) University of Cincinnati. The fifth site was the Lokmanya Tilak Memorial General Hospital located in India. Clinical personnel in these five sites collected data using the Infrascanner and Computer Tomography (CT) scans (the gold standard in detecting hematomas). All the CT scans were read by the expert radiologist from an independent site, John’s Hopkins University Hospital. The evaluation of the Infrascanner measurements in comparison to the CT scans is based on a total of 431 patient data where 122 of them were hematoma cases of various sizes, depths and places. Study results address the hematomas that clinicians may expect the Infrascanner to detect in the clinical practice setting. Consistent with preclinical testing, the Infrascanner demonstrated high sensitivity (88%) in detecting hematomas  $> 3.5\text{cc}$  in volume and  $< 2.5\text{ cm}$  from the surface of the brain. Specificity in the Per Protocol population was 91%. The balance between specificity and sensitivity supports the utility of the Infrascanner

to prioritize patients with suspected hematomas for CT scan. It should be noted that the device is indicated for use as a screening tool and as an adjunct to the standard diagnostic workup and will not be used in lieu of this workup.

An adult population study in Seville, Spain<sup>15</sup>, evaluated a total of 35 TBI patients, ages 17-76 years. There were 19 intracranial hematomas, confirmed by a CT scan completed on all subjects within 40 minutes of the Infrascanner test. The Sensitivity in this population was 89.5% and Specificity was 81.2%.

A study in Pittsburgh<sup>16</sup> evaluated in Pediatric ICU 28 patients of 0-14 years who underwent CT as part of the clinical care not necessarily triggered by trauma. There were 12 intracranial hematomas, confirmed by a CT scan completed on all subjects within 24 hours of the Infrascanner test. The Sensitivity in this test was 100% and Specificity was 80%.

A study in Padua and Treviso, Italy,<sup>17</sup> evaluated 110 children at intermediate or high risk for intracranial injury according to the PECARN rules (GCS 14 and 15). There was only one brain hematoma case in this group (it was successfully detected). The Specificity in this test was 93% and the NPV was 100 %. The use of Infrascanner would have led to avoid ten CT scan, reducing the CT scan rate by 58.8 %

A study in Lodz, Poland,<sup>18</sup> evaluated 155 children with mild or moderate TBI. Infrascanner detected 2 out of the 3 hematomas. In the non-hematoma cases, the specificity was 98.7 %. The negative predictive value of the screening was 99.3 %. The reliability of the test was 98.1 %. The aim of the study was to propose a new protocol of screening patients using Infrascanner as a complement to repeated neurological examination and medical history review. The results of this study led to the adoption of the Infrascanner as part of the standard of pediatric care in Poland.<sup>19</sup>

A study in Moscow, Russia<sup>20</sup> evaluated Infrascanner ability to detect ICH among 95 children having experienced mild traumatic head trauma. 42 children with associated medium-high risk (GCS 13-14) received an evaluation by neurosurgeon, Infrascanner scan, and had a CT. 53 children with associated low risk (GCS 15) received a scan with the Infrascanner and were clinically monitored for 72 hours. Among the medium-high risk category the sensitivity was 100% and the specificity was 91.2%. In the low risk group, the specificity was 91.7%.

A study in Beijing, China<sup>21</sup> evaluated a total of 85 TBI patients, ages 8-89 years. There were 45 intracranial hematomas, confirmed by a CT scan completed on all subjects within 30 minutes of the Infrascanner test. The Sensitivity in this population was 95.6% and Specificity was 92.5%.

A study in a physician-staffed helicopter Emergency Medical Service (HEMS) in Nijmegen, Netherlands<sup>22</sup> evaluated a total of 25 TBI patients. There were 15 intracranial hematomas, confirmed by a CT scan completed on all subjects upon arrival to a trauma center, however, the operators didn't follow the scanning protocol. The Sensitivity in this population was 93.3% and Specificity was 78.6%.

A study in General Military Hospital in Beijing, China<sup>23</sup> evaluated a total of 102 TBI patients. There were 24 intracranial hematomas, confirmed by a CT scan completed on all subjects within 30 minutes of the Infrascanner test. The Sensitivity in this population was 100% and Specificity was 93.6%. Blood contained within scalp hematomas was found to be a major cause of false positive results with this technology.

A study in Duke University<sup>24</sup> evaluated a total of 500 TBI patients. There were 104 intracranial hematomas, confirmed by a CT scan completed on all subjects within 30 minutes of the Infrascanner test. For all patients with CT-proven bleeds, irrespective of size, initial scans localized the bleed to the appropriate quadrant with a sensitivity of 86% and specificity of 96% compared to CT scan. For extra-axial bleeds >3.5ml, sensitivity and specificity were 94% and 96%, respectively. For longitudinal serial

rescans with the Infrascanner, sensitivity was 89% (<4 days from injury: sensitivity=99%) and specificity was 96%. In those patients who required surgical intervention, the device demonstrated 100% sensitivity.

A study in a major trauma center in London<sup>25</sup> evaluated a total of 205 TBI patients. There were 87 intracranial hematomas, confirmed by a CT scan completed on all subjects upon arrival. Unfortunately, only the study PI was trained and he didn't train the scanner operators. Without proper training, the Sensitivity was 89.4% and Specificity was 48.7%. Similar to the Dutch helicopter study, the importance of training and following procedure protocol are evident.

## References

- <sup>1</sup> CDC. Surveillance Report of Traumatic Brain Injury-related Emergency Department Visits, Hospitalizations, and Deaths—United States, 2014. Available from: [www.cdc.gov/traumaticbraininjury/get\\_the\\_facts.html](http://www.cdc.gov/traumaticbraininjury/get_the_facts.html).
- <sup>2</sup> Global, regional, and national burden of traumatic brain injury and spinal cord injury, 1990–2016: a systematic analysis for the Global Burden of Disease Study 2016. *Lancet Neurol* 2019; 18: 56–87. [http://dx.doi.org/10.1016/S1474-4422\(18\)30415-0](http://dx.doi.org/10.1016/S1474-4422(18)30415-0).
- <sup>3</sup> Seelig JM, Becker DP, Miller DP, *et al.* (1985). Traumatic acute subdural hematoma: major mortality reduction in comatose patients treated within four hours. *N Engl J Med* 304:1511-1518.
- <sup>4</sup> Narayan RK, Michel ME, Ansell B, Baethmann A, Biegon A, Bracken MB, Bullock MR, Choi SC, Clifton GL, Contant CF, Coplin WM, Dietrich WD, Ghajar J, Grady SM, Grossman RG, Hall ED, Heetderks W, Hovda DA, Jallo J, Katz RL, Knoller N, Kochanek PM, Maas AI, Majde J, Marion DW, Marmarou A, Marshall LF, McIntosh TK, Miller E, Mohberg N, Muizelaar JP, Pitts LH, Quinn P, Riesenfeld G, Robertson CS, Strauss KI, Teasdale G, Temkin N, Tuma R, Wade C, Walker MD, Weinrich M, Whyte J, Wilberger J, Young AB, Yurkewicz L. 2002. Clinical trials in head injury. *Journal of Neurotrauma*, Volume 19, Issue 5, Pages 503-557.
- <sup>5</sup> Xiong Y, Lee CP, and Peterson PL. 2001. Mitochondrial dysfunction following traumatic brain injury. In *Head Trauma: Basic, Preclinical, and Clinical Directions*. Miller LP and Hayes RL, eds. Co-edited by Newcomb JK. 2001, John Wiley and Sons, Inc. New York. Pages 257-280
- <sup>6</sup> “The epidemiology and impact of traumatic brain injury: a brief overview”, *The Journal of Head Trauma Rehabilitation*, Sept. 1, 2006.
- <sup>7</sup> Foulkes M, Eisenberg HM, Jane JA, *et al.* The Traumatic Coma Data Bank: design, methods, and baseline characteristics. *J Neurosurg* 1991; 75(suppl):S8-S13.
- <sup>8</sup> J.J. Rivas, R.D. Lobato, R. Sarabia, F. Cordobes, A. Cabrera, and P. Gomez, "Extradural hematoma: analysis of factors influencing the courses of 161 patients," *Neurosurgery* 23 (1), 44-51 (1988).
- <sup>9</sup> R. Bullock, O. Hannemann, L. Murrey, and G.M. Teasdale, "Recurrent hematoma following craniotomy for traumatic intracranial mass," *J Neurosurg* 72 (1), 9-14 (1990).
- <sup>10</sup> B. Jennett, G. Teasdale, S. Galbraith, J. Pickard, H. Grant, R. Braakman, C. Avezzatt, A. Maas, J. Minderhoud, C.J. Vecht, J. Heiden, R. Small, W. Caton, and T. Curze, "Severe head injuries in three countries," *J Neurol Neurosurg Psych* 40 (3), 291-298 (1977).

- 
- <sup>11</sup> T. Braun, U. Kunz, C. Schulz, A. Lieber, C. Willy, "Near-infrared spectroscopy for the detection of traumatic intracranial hemorrhage. Feasibility study in a German army field hospital in Afghanistan", *Der Unfallchirurg*, Jan 2014: 1-8. <https://doi.org/10.1007/s00113-013-2549-0>
- <sup>12</sup> S. Krauss, S. Sanjakdar, A. Wilson, B. Dacanay, L. Jasper, A. Adler, T. Funari, "Quickly Evaluating an Emerging Medical Technology Using Feedback From the Field: A Case Study of the BrainScope One and Infrascanner 2000 User Evaluation", *Military Medicine* 2020, usaa069, <https://doi.org/10.1093/milmed/usaa069>
- <sup>13</sup> Robertson CS, Gopinath SP and Chance B, "Use of Near-Infrared Spectroscopy to Identify Traumatic Intracranial Hematomas," *J. Biomed. Opt.* 2, 33 – 41, 1997. <https://doi.org/10.1117/12.261680>
- <sup>14</sup> Robertson, C., Zager, E., Narayan, R., Handly, N., Sharma, A., Hanley, D., Garza, H., Maloney-Wilensky, E., Plaum, J., and Koenig, C., 2010, "Clinical Evaluation of a Portable Near-Infrared Device for Detection of Traumatic Intracranial Hematomas," *Journal of Neurotrauma*, 27(9), pp. 1597-1604. <https://doi.org/10.1089/neu.2010.1340>
- <sup>15</sup> Leon-Carrion J, Dominguez-Roldan JM, Leon-Dominguez U, Murillo-Cabezas F: The Infrascanner, a handheld device for screening in situ for the presence of brain haematomas, *Brain Injury*, 2010; 24(10): 1193-1201. <https://doi.org/10.3109/02699052.2010.506636>
- <sup>16</sup> R. Salonia, M.J. Bell, P.M. Kochanek, R.P. Berger, "The Utility of Near Infrared Spectroscopy in Detecting Intracranial Hemorrhage in Children", *Journal of Neurotrauma*. April 2012, Vol. 29, No. 6: 1047–1053. <https://doi.org/10.1089/neu.2011.1890>
- <sup>17</sup> Bressan S, Daverio M, Martinolli F, Dona D, Mario F, Steiner IP, Da Daltto L: The use of handheld near-infrared device (Infrascanner) for detecting intracranial haemorrhages in children with minor head injury. *Childs Nerv Syst* (2014). 30:3, 477-484. <https://doi.org/10.1007/s00381-013-2314-2>
- <sup>18</sup> Lewartowska-Nyga D, Nyga K, and Skotnicka-Klonowicz G, Can Infrascanner be useful in hospital emergency departments for diagnosing minor head injury in children? *Developmental period medicine*, 2017; 21(1):51-59.
- <sup>19</sup> Grażyna Skotnicka-Klonowicz, Jan Godziński, Adam Hermanowicz, Jan Wendland, Erwin Strzesak, Krzysztof Strzyżewski, Piotr Czauderna, "Management of minor to moderate head trauma in children - Guidelines of the Polish Association of Pediatric Surgeons", *Standardy Medyczne/Problemy Chirurgii Dziecięcej*, 2014, vol. 4: 42-50.
- <sup>20</sup> Semenova, AH., Marshintev, V., Melnikov, V., Meshcheryakov, V., Adayev, R., Lukyanov, VI. Infrascanner in the Diagnosis of Intracranial damage in Children with traumatic brain Injuries. *Brain Injury* 2016, 30(1):18-22. <https://doi.org/10.3109/02699052.2014.989401>
- <sup>21</sup> Long Xu, Xiaogang Tao, Weiming Liu, Yanong Li, Jun Ma, Te Lu, Bo Han, Baiyun Liu, Yuanli Zhao, Jingsheng Li, Jizong Zhao, Portable near-infrared rapid detection of intracranial hemorrhage in Chinese population, *J Clin Neurosci* (2017), <https://dx.doi.org/10.1016/j.jocn.2017.02.056>.
- <sup>22</sup> Peters J, Van Wageningen B, Hoogerwerf N, Tan E. Near-infrared spectroscopy: a promising prehospital tool for management of traumatic brain injury. *Prehosp Disaster Med*. 2017;32(3):1-5. <https://doi.org/10.1017/S1049023X17006367>.

- 
- <sup>23</sup> Liang CY, Yang Y, Shen CS, Wang HJ, Liu NM, Wang ZW, Zhu FL, Xu RX, Chinese military evaluation of a portable near-infrared detector of traumatic intracranial hematomas, *Military Medicine* 2018;183(7-8): e318-e323, <https://doi.org/10.1093/milmed/usx088>.
- <sup>24</sup> Gramer RM, Shlobin NA, Yang Z, Niedzwiecki D, Haglund MM., Fuller AT, Clinical Utility of Near-Infrared Device in Detecting Traumatic Intracranial Hemorrhage: A Pilot Study toward Application as an Emergent Diagnostic Modality in a Low-Resource Setting. *Journal of Neurotrauma*, Aug 2022. <https://doi.org/10.1089/neu.2021.0342>
- <sup>25</sup> Kontojannis V, Hostettler I, Brogan RJ, Raza M, Harper-Payne A, Kareem H, Boutelle M, Wilson M, “Detection of intracranial hematomas in the emergency department using near infrared spectroscopy”, *Brain Injury* 2019, 33:7, 875-883, <https://doi.org/10.1080/02699052.2019.1610796>